










Cite this article as: Coutinho e Silva RS, Wiggenhauser LM, Simas R, Zanoni FL, Medeiros G, da Silva FB *et al.* Thoracic bilateral sympathectomy attenuates oxidative stress and prevents ventricular remodelling in experimental pulmonary hypertension. *Eur J Cardiothorac Surg* 2021; doi:10.1093/ejcts/ezab549.

# Thoracic bilateral sympathectomy attenuates oxidative stress and prevents ventricular remodelling in experimental pulmonary hypertension

Raphael dos Santos Coutinho e Silva <sup>a</sup>, Lucas Moritz Wiggenhauser <sup>b</sup>, Rafael Simas <sup>c</sup>,  
Fernando Luiz Zanoni <sup>a</sup>, Geisla Medeiros <sup>d</sup>, Fernanda Beatriz da Silva<sup>d</sup>, Daniel Cury Ogata <sup>d</sup>,  
Ana Cristina Breithaupt-Faloppa <sup>a</sup>, Guido Krenning <sup>b</sup> and Luiz Felipe Pinho Moreira <sup>a,\*</sup>

<sup>a</sup> Laboratório Cirúrgico de Pesquisa Cardiovascular (LIM-11), Instituto do Coração (Incor), Hospital das Clínicas HCFMUSP, Faculdade de Medicina, Universidade de São Paulo, São Paulo, Brazil

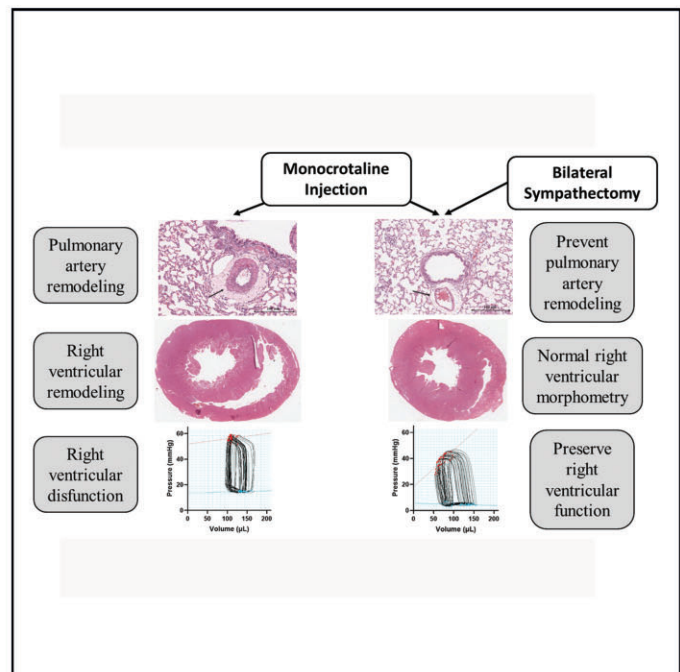
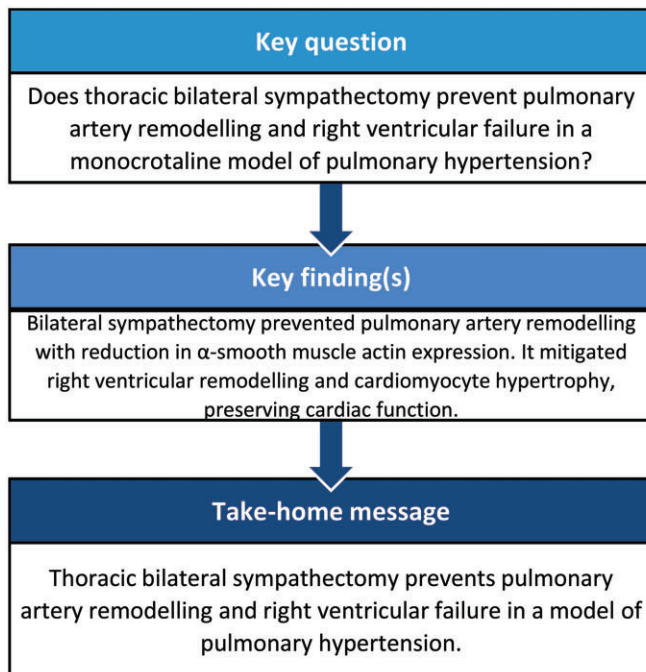
<sup>b</sup> Department of Pathology and Medical Biology, Laboratory for Cardiovascular Regenerative Medicine, University Medical Center Groningen, University of Groningen, Groningen, Netherlands

<sup>c</sup> The Rolf Luft Research Center for Diabetes and Endocrinology, Karolinska Institutet, Stockholm, Sweden

<sup>d</sup> Universidade do Vale do Itajaí, UNIVALI, Santa Catarina, Brazil

\* Corresponding author. Laboratório Cirúrgico de Pesquisa Cardiovascular (LIM-11), Instituto do Coração (Incor), Hospital das Clínicas HCFMUSP, Faculdade de Medicina, Universidade de São Paulo, São Paulo, BR. Av. Dr Eneas Carvalho de Aguiar, 44, Sao Paulo, SP 05403-900, Brazil. Tel: +551126615075; e-mail: luiz.moreira@incor.usp.br (L.F.P. Moreira).

Received 19 July 2021; received in revised form 27 October 2021; accepted 21 November 2021



## Abstract

**OBJECTIVES:** Pulmonary arterial hypertension (PAH) is a cardiopulmonary disease that affects the pulmonary vasculature, leading to increased afterload and eventually right ventricular (RV) remodelling and failure. Bilateral sympathectomy (BS) has shown promising

results in dampening cardiac remodelling and dysfunction in several heart failure models. In the present study, we investigated whether BS reduces pulmonary arterial remodelling and mitigates RV remodelling and failure.

**METHODS:** PAH was induced in male Wistar rats by intraperitoneal injection of monocrotaline. Rats were divided into 3 groups, involving untreated PAH ( $n = 15$ ), BS-treated PAH ( $n = 13$ ) and non-manipulated control rats ( $n = 13$ ). Three weeks after PAH induction, the rats were anaesthetized and RV function was assessed via the pressure-volume loop catheter approach. Upon completion of the experiment, the lungs and heart were harvested for further analyses.

**RESULTS:** BS was found to prevent pulmonary artery remodelling, with a clear reduction in  $\alpha$ -smooth muscle actin and endothelin-1 expression. RV end-systolic pressure was reduced in the BS group, and preload recruitable stroke work was preserved. BS, therefore, mitigated RV remodelling and cardiomyocyte hypertrophy and diminished oxidative stress.

**CONCLUSIONS:** We showed that thoracic BS may be an important treatment option for PAH patients. Blockade of the sympathetic pathway can prevent pulmonary remodelling and protect the RV from oxidative stress, myocardial remodelling and function decay.

**Keywords:** Sympathetic blockade • Pulmonary hypertension • Ventricular remodelling • Pulmonary artery remodelling • Oxidative stress

### ABBREVIATIONS

BS	Bilateral sympathectomy
NO	Nitric oxide
PADN	Pulmonary artery denervation
PAH	Pulmonary arterial hypertension
PASMC	Pulmonary arterial smooth muscle cell
PVR	Pulmonary vascular resistance
RV	Right ventricular
SNS	Sympathetic nervous system

## INTRODUCTION

Pulmonary arterial hypertension (PAH) is a cardiopulmonary disease that affects both the pulmonary vasculature and the right ventricle (RV). Irrespective of the primary aetiology, PAH is characterized by vascular remodelling of the pulmonary artery resulting in increased pulmonary vascular resistance (PVR), which leads to high RV afterload and the development of RV failure—the leading cause of death in PAH patients [1, 2]. While current therapeutic approaches are symptomatic and based on vasodilative and antiproliferative drugs, none of the standard treatments are curative [3].

A vicious cycle between states of oxidative stress and inflammation aggravates PAH development and activates the sympathetic nervous system (SNS) [4]. Norepinephrine released by the SNS promotes pulmonary arterial smooth muscle cell (PASMC) remodelling via the ERK-1/2 pathway [5]. Autonomic nervous system imbalance is associated with disease progression, which leads to RV failure and increased mortality [6]. Expectedly, sympathetic blockade has been shown to be effective in dampening ventricular dysfunction in several heart failure models.

Bilateral sympathectomy (BS) has been observed to prevent cardiac remodelling and preserve left ventricular (LV) function in experimental models of myocardial infarction [7] and dilated cardiomyopathy [8]. In PAH models, partial sympathetic blockade inhibited ERK-1/2-mediated vascular remodelling in PASMCs [9] and attenuated PAH progression via the nitric oxide (NO) pathway [10]. Nevertheless, the underlying mechanisms of sympathetic blockade still remain elusive.

As SNS seems to play a central role in PAH development and RV failure, we aimed to investigate whether BS ameliorates pulmonary artery remodelling and secondary RV failure and to

evaluate its mechanism of action in a monocrotaline-induced PAH rat model.

## MATERIALS AND METHODS

### Ethics statement

All experiments were performed in accordance to the Ethical Principles for Animal Research proposed by the Brazilian College of Animal Experimentation. Approval was obtained from the Animal Subject Committee of the University of São Paulo Medical School (CEUA-FMUSP # 033/17).

### Animals and procedures

Male Wistar rats, weighing an average of  $350 \pm 30$  g, were randomly divided into 3 groups: untreated PAH group (PAH,  $n = 15$ ); BS-treated PAH group (BS,  $n = 13$ ); and control group ( $n = 13$ ). PAH was induced in both the PAH and BS groups through a single intraperitoneal injection of monocrotaline (60 mg/kg; Sigma Aldrich, San Luís, MO, USA), while control group was not manipulated.

Before PAH induction in the BS group, bilateral sclerosis of the stellate ganglion was performed as previously described [8]. BS was confirmed by the observation of bilateral and non-reversible palpebral ptosis.

### Right ventricular function evaluation

Three weeks after PAH induction, the rats were submitted to RV function evaluation using a pressure-volume conductance system. Further details are described in the [Supplementary Material](#).

### Histological and immunohistochemistry analyses

At the end of the experimental protocol, all the rats were euthanized by exsanguination. The lungs and heart were removed and processed for analyses.

### Lung and heart homogenate assays

Lung and heart samples were weighed and homogenized for further analyses. Detailed procedures are described in the [Supplementary Material](#).

## Cardiomyoblast assays

Rat H9C2 cardiomyoblasts were used to assess mitochondrial oxidative stress and hypertrophy. Detailed procedures are described in the [Supplementary Material](#).

## Statistical analysis

All data were analysed using Prism 9.0 (GraphPad Software Inc, CA, USA) and are expressed as median and interquartile interval. The minimal number of 7 rats per group was defined based on the expected difference of more than one interquartile variation in morphometric and haemodynamic variables. The differences between groups were assessed via the Kruskal–Wallis test, followed by the Benjamini–Hochberg method of false discovery rate, with *P*-values adjusted to 0.05 to account for adjusting for each end-point for the 3 pairwise comparisons.

## RESULTS

No deaths occurred in the control group, while 2 deaths were observed in the untreated PAH group. BS decreased PAH-associated mortality, with no deaths reported in the BS group. At the end of the experimental protocol, the rats were randomly assigned for either haemodynamic analyses (*n*=7 per group) or molecular and biochemical analyses (*n*=6 per group). Morphological data of the lung and heart were obtained in all the surviving animals. Both exhaled O<sub>2</sub> and CO<sub>2</sub> and blood gases (PO<sub>2</sub> and PCO<sub>2</sub>) did not differ between the groups.

### BS decreased pulmonary artery remodelling, atelectasis and fibrosis

As expected, the pulmonary arterial and arteriolar walls were thicker in untreated PAH rats compared to control rats (Fig. 1A; PAH: 24 127 ± 11 854 μm<sup>2</sup>; control: 8787 ± 2666 μm<sup>2</sup>). BS decreased arterial wall thickness by 52.3%, and the arterial wall thickness of BS-treated PAH rats did not differ from that of control rats.

Untreated PAH rats exhibited increased arterial muscularization compared to control rats, as evidenced by an increase in αSMA-positive areas (Fig. 1B). BS inhibited the increase in muscularization when compared to the untreated PAH group and had a tendency to decrease muscularization when compared to the control group.

Besides pulmonary arterial remodelling, untreated PAH rats demonstrated a higher degree of pulmonary atelectasis when compared to control rats (Table 1). BS reduced, but did not mitigate, pulmonary atelectasis in PAH rats to levels similar to those of the control group. Atelectasis did not stem from the occurrence of pulmonary oedema or inflammation, as these did not differ between the groups. However, pulmonary fibrogenesis was increased in untreated PAH rats and was reduced in the BS group. Thus, BS reduced pulmonary arterial remodelling and atelectasis in PAH rats, presumably by mitigating fibrogenic responses.

### Noradrenaline decrease attenuated vascular constriction

A decrease in noradrenaline expression (Fig. 2A), but not in adrenaline expression (Fig. 2B), was observed in the BS group.

ET-1 expressions in lung blood vessels did not differ between the control and PAH groups. However, ET-1 expression in the BS group was significantly lower than that of the PAH group (Fig. 2C). VEGF expression in lung homogenates of the PAH group was lower than that of the control group. BS did not alter VEGF expression (Fig. 2D). In terms of NO metabolites, no (significant) differences were shown in the nitrate (Fig. 2E) and nitrite (Fig. 2F) levels of PAH and BS lung homogenates.

### BS mitigated RV remodelling and dysfunction

Untreated PAH rats showed greater RV remodelling compared to control rats (Fig. 3). In PAH rats, right ventricular end-systolic pressure (RVESP) and pulmonary vascular resistance (PVR) were significantly higher than those of control rats, while HR was not (Table 2), suggesting the development of RV failure. Indeed, the indicators for contraction efficacy, including PRSW and *dP/dT* max, were lower in PAH rats than in control rats, while those for relaxation efficacy did not differ between the 2 groups. BS restored PRSW and normalized both RVESP/MAP and PVR, which may be associated with the prevention of RV failure (Fig. 4A). No differences in the remaining parameters were observed among the groups.

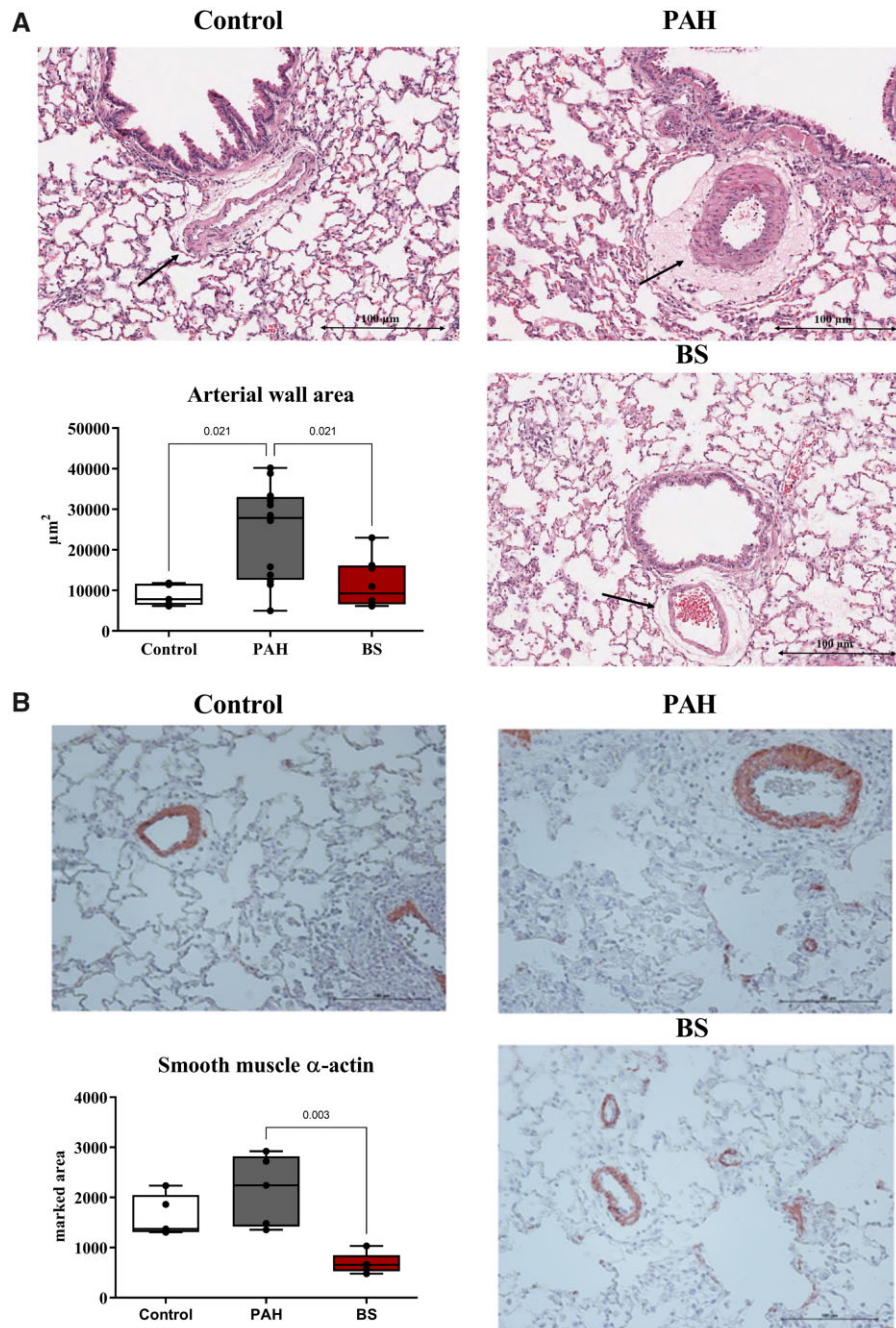
PAH rats demonstrated maladaptive remodelling with enlarged RV chambers and thicker RV wall than the control group (Fig. 3). BS was shown to prevent RV chamber dilation in relation to the PAH group. Furthermore, the BS group exhibited thinner RV walls compared to the PAH group, but no differences were observed in terms of LV wall thickness. There was no difference in the percentage of RV myocardial connective tissue between the 3 groups [control: 0.7% (0.2–1.6); PAH: 1.1% (0.3–3.7); BS: 0.7% (0.1–1.4); *P* = 0.318].

### RV failure associated with cardiomyocyte hypertrophy and mitochondrial stress, which were precluded by BS

The RV failure in PAH rats coincided with RV cardiomyocyte hypertrophy, which was precluded by BS (Fig. 5A). LV cardiomyocytes were unaffected, and their sizes did not differ between the groups. Cardiomyocyte hypertrophy associates with mitochondrial stress. Indeed, myocyte mtDNA copy number was lower in PAH rats than in control rats, and the loss of mtDNA was precluded by BS (Fig. 5B). Concurrently, oxidative stress, as indicated by radical scavenging activity (Fig. 5C) and lipid peroxidation products (Fig. 5D), was apparent in the RV of untreated PAH rats and was also mitigated by BS.

### Sympathetic stimuli associated with increased oxidative stress in cardiomyoblasts

Adrenergic stimulation by phenylephrine is known to induce cellular hypertrophy in cultured cardiomyoblasts. Stimulated cardiomyoblasts in our study showed increased mitochondrial oxidative stress, which was mitigated by the strong antioxidant Trolox (Fig. 6A). As expected, phenylephrine stimulation increased the activity of a hypertrophy-reported construct, which was reduced by co-treatment with Trolox (Fig. 6B). These data suggest that adrenergic stimulation of cardiomyocytes directly evokes mitochondrial stress, which can culminate to cellular hypertrophy.



**Figure 1:** Arterial wall ( $n = 13$ ) and  $\alpha$ -actin smooth muscle analysis ( $n = 6$ ). White: control group; grey: pulmonary arterial hypertension group; red: bilateral sympathectomy group. PAH: pulmonary arterial hypertension; BS: bilateral sympathectomy. **(A)** Representative photomicrography under  $20\times$  augmentation of the arteries (arrow) stained with haematoxylin and eosin. Kruskal-Wallis  $P$ -value = 0.013. **(B)** Representative photomicrography under  $20\times$  augmentation of the arteries (arrow) marked for smooth muscle  $\alpha$ -actin, counterstained with haematoxylin. Kruskal-Wallis  $P$ -value < 0.001.

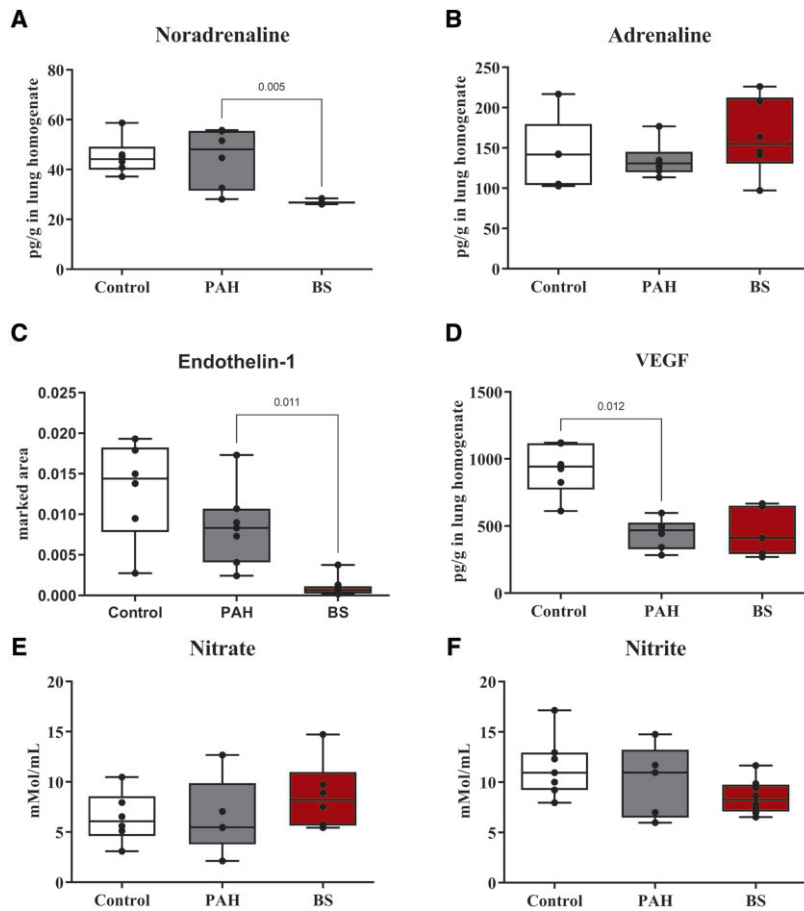
**Table 1:** Lung histology

	Control, $n = 13$	PAH, $n = 13$	BS, $n = 13$	$P$ -Value
Pulmonary atelectasis, %	0.0 (0.0–3.9) <sup>a</sup>	17.8 (0.0–48.9)	0.0 (0.0–15.0) <sup>a</sup>	0.0001
Pulmonary oedema, %	1.7 (0.6–3.4)	6.1 (2.1–13.3)	6.2 (0.0–7.1)	0.1189
Inflammatory infiltrate, %	2.8 (1.0–6.7)	4.5 (0.2–9.1)	7.0 (1.0–10.4)	0.4480
Pulmonary fibrosis, %	8.9 (5.6–15.6) <sup>a</sup>	21.1 (11.1–41.7)	12.2 (6.7–22.2) <sup>a</sup>	0.0140

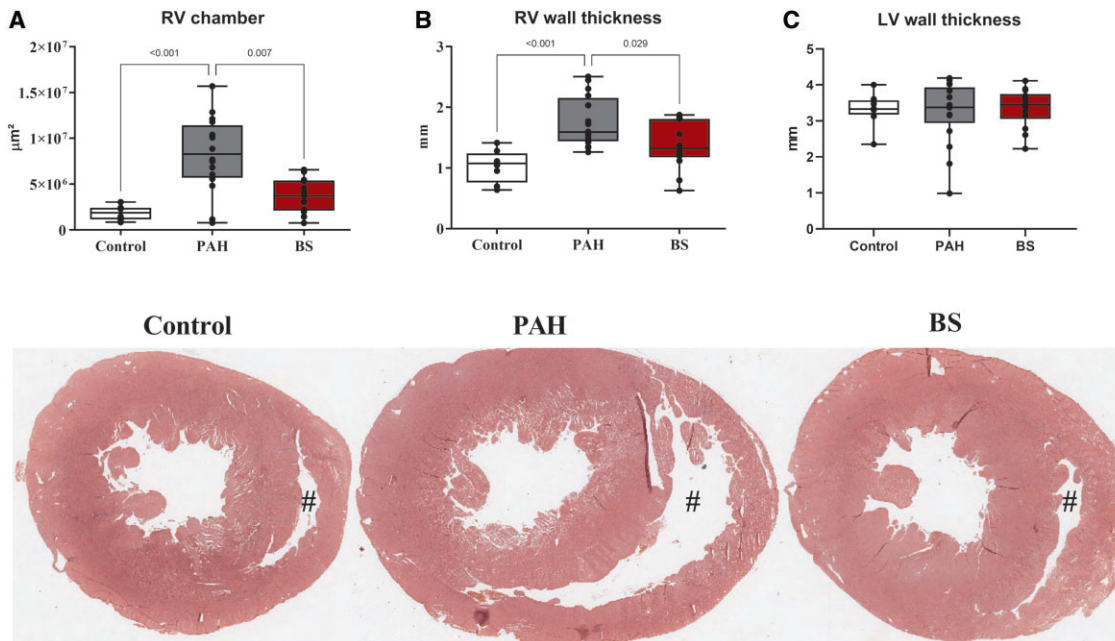
Data presented as median and interquartile interval.

<sup>a</sup>Benjamini-Hochberg method of false discovery rate  $P < 0.05$  versus PAH group.

BS: bilateral sympathectomy; PAH: pulmonary arterial hypertension.



**Figure 2:** Noradrenaline (A), adrenaline (B), endothelin-1 (C) and VEGF (D) protein expression and nitric oxide metabolites (E and F) in lung homogenates. *N* = 7 per group. White: control group; grey: pulmonary arterial hypertension group; red: bilateral sympathectomy group. BS: bilateral sympathectomy; PAH: pulmonary arterial hypertension.



**Figure 3:** Cardiac morphometric analyses and representative photomicrographs of gross heart sections stained with haematoxylin and eosin. Right ventricular chamber (A), right ventricular (B) and left ventricular (C) wall thickness. *N* = 13 per group. White: control group; grey: pulmonary arterial hypertension group; red: bilateral sympathectomy group. BS: bilateral sympathectomy; PAH: pulmonary arterial hypertension. #The lumen of the right ventricle.

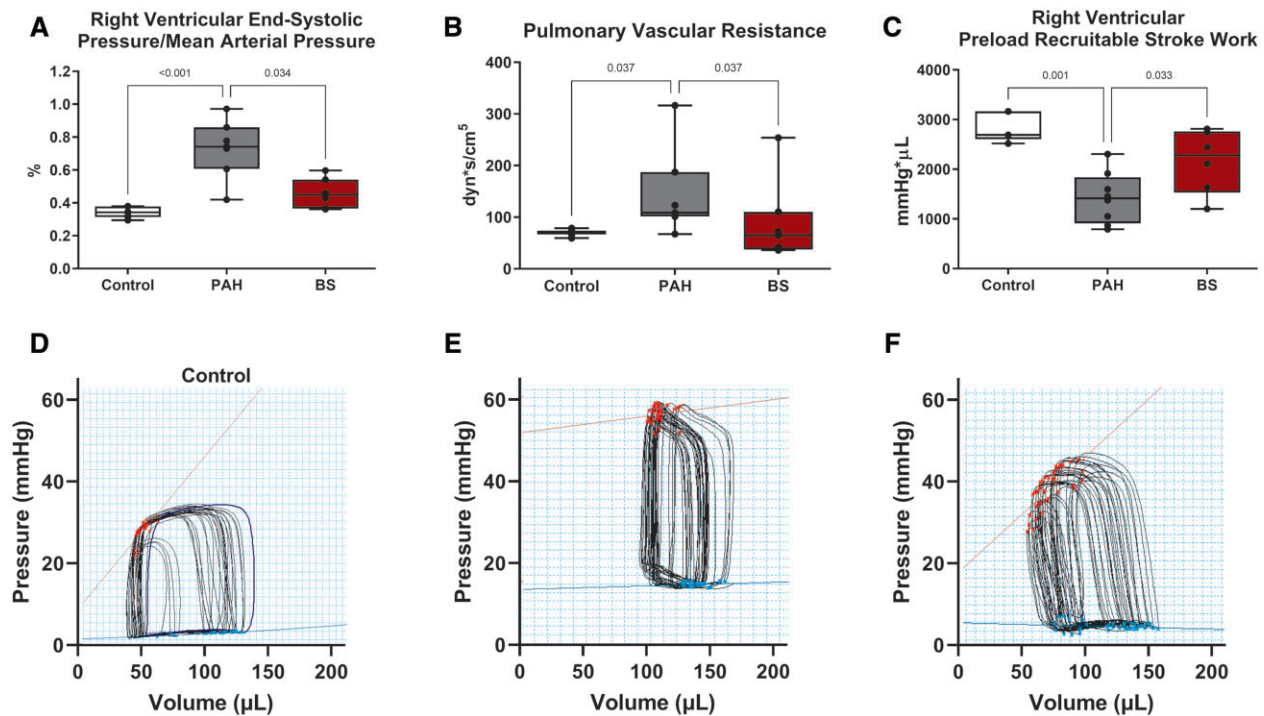
**Table 2:** Heart function

	Control, n = 7	PAH, n = 7	BS, n = 7	P-Value
<b>Global haemodynamics</b>				
Heart rate, bpm	328 (263 to 353)	319 (289 to 370)	334 (283 to 372)	0.533
Mean arterial pressure, mmHg	68 (63 to 85)	82 (71 to 95)	93 (78 to 105)	0.085
Cardiac output, ml/min	24.6 (13.3 to 36)	26.2 (8.9 to 45.4)	27.1 (8.4 to 44)	0.945
<b>RV function</b>				
End-diastolic pressure, mmHg	2.2 <sup>a</sup> (1.2 to 6.2)	8.9 (1.7 to 13.9)	1.6 <sup>a</sup> (0.3 to 12.8)	0.0007
End-systolic pressure, mmHg	25 <sup>a</sup> (18 to 29)	52 (36 to 82)	42 (28 to 53)	0.0005
End-diastolic volume, $\mu$ l	120.9 (85.7 to 171.3)	121 (83.2 to 178.6)	134.4 (95.9 to 176.2)	0.492
End-systolic volume, $\mu$ l	54.9 (30.9 to 71.7)	57.3 (20.3 to 81.8)	66 (10.1 to 85.5)	0.693
Ejection fraction, %	65 (36 to 87)	70 (33 to 86)	56 (31 to 71)	0.339
Stroke volume, $\mu$ l	79 (40.5 to 106)	80.1 (27.3 to 122.7)	72.8 (26.5 to 126.2)	0.978
Stroke work, mmHg ml	2.06 (0.58 to 3.54)	2.2 (0.39 to 10.33)	3.09 (0.39 to 4.85)	0.917
dP/dT min, mmHg/s	-860 <sup>a</sup> (-1349 to -600)	-2332 (-6298 to -1204)	-2229 (-2557 to -910)	0.001
dP/dT max, mmHg/s	1072 <sup>a</sup> (862 to 1861)	2443 (1465 to 7299)	2166 (1294 to 2850)	0.002
tau, ms	14.5 (8.9 to 28.7)	11.6 (3.1 to 34.5)	10.8 (7.7 to 33.2)	0.850

Global and right ventricular haemodynamics parameters. Data are presented as median and interquartile interval.

<sup>a</sup>Benjamini-Hochberg method of false discovery rate  $P < 0.05$  versus PAH group.

BS: bilateral sympathectomy; PAH: pulmonary arterial hypertension; RV: right ventricular.

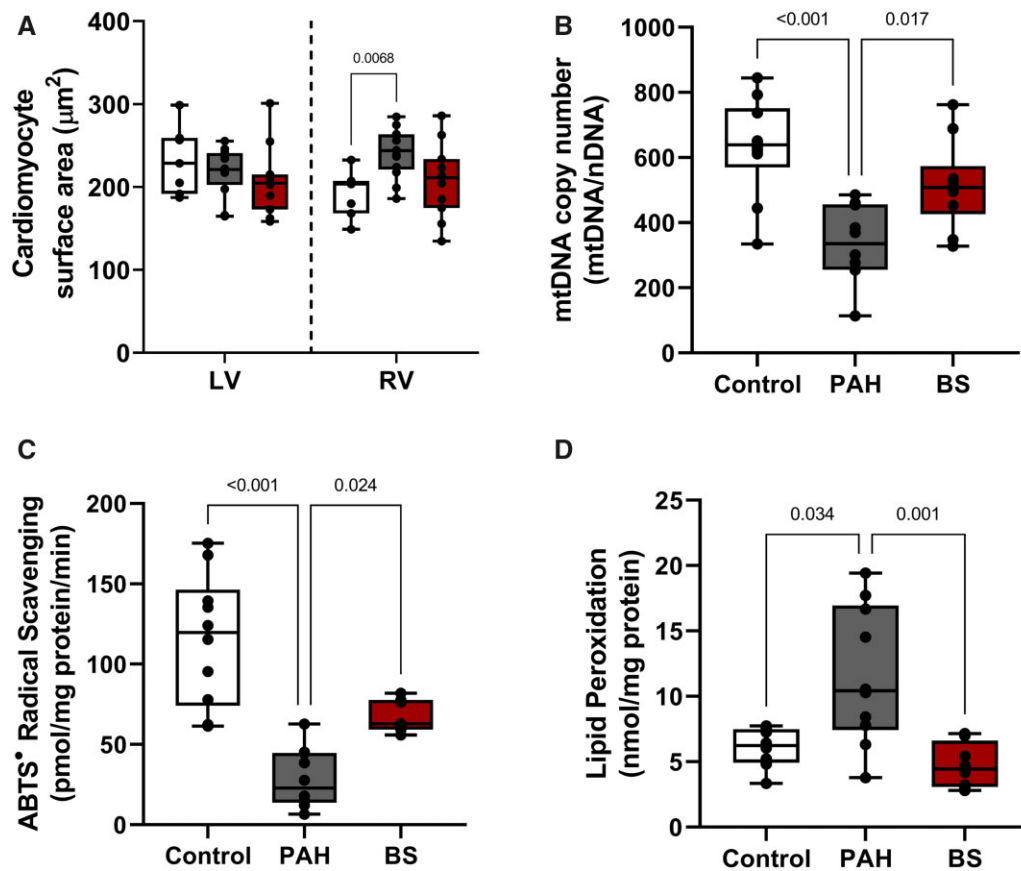


**Figure 4:** Data for right ventricular end-systolic pressure/mean arterial pressure relation (A), pulmonary vascular resistance (B) and right ventricular preload recruitable stroke work (C). The representative pulmonary vein loop response to preload manoeuvre of each group (D-F).  $N = 7$  per group. White: control group; grey: pulmonary arterial hypertension group; red: bilateral sympathectomy group. BS: bilateral sympathectomy; PAH: pulmonary arterial hypertension.

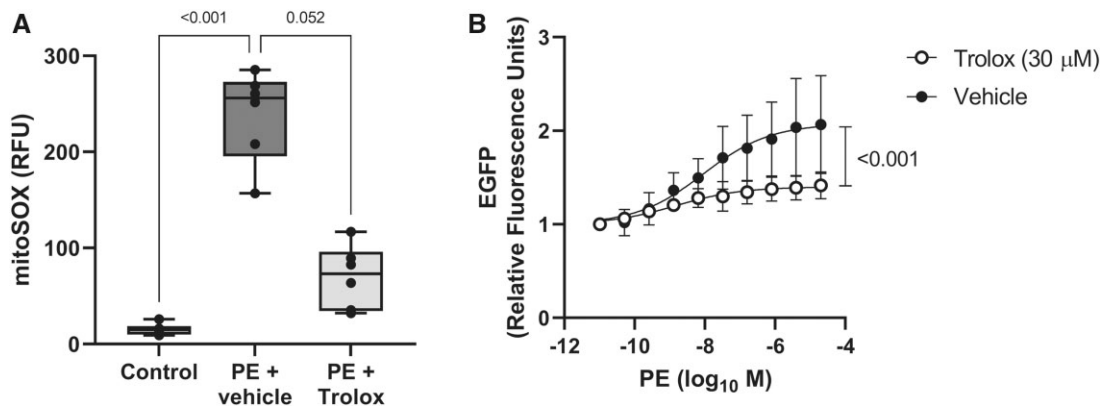
## DISCUSSION

Our study showed that BS can mitigate pulmonary vascular remodelling and RV failure in a rat model of PAH. Untreated PAH rats presented with pulmonary blood vessel wall hypertrophy, accompanied by increased PVR, lung fibrosis and atelectasis. Such pathological changes were mitigated by BS. Pulmonary vascular remodelling and increased PVR result in the

development of RV failure, which represents the primary cause of mortality in PAH patients. Untreated PAH rats developed RV failure secondary to PAH and presented with increased PVR, RVESP,  $dP/dT$  max and RVESP/MAP, as well as decreased PRSW. At the pathophysiological level, the RV of PAH rats showed maladaptive hypertrophy and dilatation, with cardiomyocyte hypertrophy, oxidative stress and diminished mitochondrial copy number, which were mitigated following treatment with BS.



**Figure 5:** Right ventricular cellular analyses. Cardiomyocyte cellular hypertrophy (A) measured in the right and left ventricle. Mitochondrial copy number (B). Radical scavenging activity (C). Lipid peroxidation (D).  $N=13$  per group. White: control group; grey: pulmonary arterial hypertension group; red: bilateral sympathectomy group. BS: bilateral sympathectomy; PAH: pulmonary arterial hypertension.



**Figure 6:** H9C2 cardiomyoblast assays. MitoSOX analysis (A) and hypertrophy reporter assay (B).  $N=6$  per group. White: control group; dark grey: phenylephrine + vehicle group; light grey: phenylephrine + Trolox group. PE: phenylephrine.

Hence, we conclude that BS can elicit beneficial effects in experimental PAH and may offer a therapeutic benefit to PAH patients.

Sympathetic overactivity has been linked to pulmonary artery remodelling in PAH [9]. In pulmonary arteries, vascular contraction is primarily controlled by the  $\alpha_1$ -adrenoceptor, which has a high affinity for norepinephrine. Norepinephrine induces PSMCs [5], which results in increased muscularization of the pulmonary arteries. Blockade of the sympathetic tone attenuates

ERK activation and, thus, diminishes norepinephrine-induced pulmonary artery muscularization [9].

Sympathetic blockade has been investigated as an alternative to pharmacological therapy in the treatment of PAH. Pulmonary artery denervation (PADN) represents one of the alternative treatments based on modulation of the sympathetic system. PADN was performed on a monocrotaline-induced PAH dog model and was shown to improve haemodynamics and

pulmonary artery remodelling [11]. Chen *et al.* evaluated the effects of PADN on patients with idiopathic PAH with 3 months of follow-up. PADN decreased mean pulmonary arterial pressure and improved the 6-min walk test [12]. In a larger study [13] involving 66 patients who underwent PADN and discontinued other targeted treatment, 94% reported at least a 10% decrease in mean pulmonary arterial pressure within 1 year of follow-up. However, no control group was included in this study.

Thoracic sympathetic blockade has emerged as an alternative management of PAH [9, 10]. In this regard, a left superior cervical ganglion blockade has been reported to prevent PASM proliferation and increase NO availability in the lungs [10]. Similarly, transection of the right cervical sympathetic trunk suppressed pulmonary artery remodelling and prevented RV failure [9]. In a myocardial infarction model [7], BS has been proven more effective in protecting the myocardium from remodelling than unilateral sympathectomy. Based on this, the present study opted for bilateral, rather than unilateral, sympathetic blockade, and aimed to protect both the RV and the pulmonary arteries.

Endothelial dysfunction in the pulmonary arteries contributes to vascular remodelling and the increase in PVR in PAH [14]. In our model, ET-1 did not differ between the control and PAH groups. However, serum ET-1 levels have been described to be elevated in PAH patients [1]. In healthy subjects, noradrenaline and ET-1 synergism regulate vascular tone [15]. In our study, BS decreased noradrenaline levels in the lungs, consequently diminishing ET-1 expression in the pulmonary blood vessels. As a consequence, vasoconstriction was decreased, as observed by the lowered PVR and  $\alpha$ -SMA expression, which associated with decreased vascular proliferation in this study and others [9, 16]. ET-1 is a potent vasoconstrictor associated with PASM vascular remodelling, and PVR increases with PAH progression. Notably, ET-1 has been a target for PAH treatment, particularly with endothelin receptor antagonists such as Bosentan [17].

Alongside endothelin, NO plays an important role in PAH development. To analyse NO levels, most studies quantify endothelial NO synthase protein expression in the lungs. However, lung endothelial NO synthase expression is mostly unchanged or increased in experimental PAH studies, but enzyme activity is uncoupled, which produces superoxide instead of NO [18]. Since nitrates and nitrites represent the major subproducts of NO, quantifying their levels in lung homogenates allows for the assessment of NO availability in the tissue. In our study, NO levels remained unchanged in the untreated PAH group, suggesting that BS is not involved in this pathway.

In terms of VEGF, most studies have confirmed that it is overexpressed in the lungs of both chronic hypoxic and monocrotaline-induced PAH models [19, 20]. However, VEGF blockade associated with worsened pulmonary fibrosis in a rat model of PAH [21]. Interestingly, our results showed diminished VEGF lung expressions in the PAH group and the lack of effects of sympathetic blockade on these levels.

With regard to myocardial changes, BS has been shown to be superior to unilateral sympathectomy in a myocardial infarction model. BS not only preserved LV function but also prevented LV remodelling and myocardial fibrosis. In contrast, unilateral left sympathectomy failed to prevent LV remodelling, and it was associated with increased fibrosis and decay of function, probably due to the hypertrophy of the contralateral ganglion. BS was equally effective in a rat model of doxorubicin-induced heart failure. It was shown to decrease apoptotic markers and reduce myocardial fibrosis and thereby associated with maintained LV

ejection fraction and myocardial contractile efficiency, as well as increase PRSW [8]. Since RV remodelling and further heart failure represent the leading cause of death in PAH patients, RV protection is an important outcome to be analysed.

Pathological remodelling increases energy demand through unfavourable cardiac geometry, with increased neurohormonal stimulation and impaired calcium handling, which can result in mitochondrial stress and metabolic imbalance [22]. Untreated PAH rats in our study demonstrated an increase in myocardial peroxidation damage associated with diminished endogenous radical scavenging activity. The increase in oxidative stress was accompanied by a decrease in myocardial mitochondrial copy number. Sympathetic blockade by BS, therefore, associated with preserved radical scavenging activity, reduced levels of lipid peroxidation, and consequently the maintenance of mitochondrial copy number.

As a result of preserved metabolic balance, RV remodelling was prevented. By preserving myocardial reserves, thoracic BS associated with the maintenance of both cardiomyocyte size and RV geometry. While RV hypertrophy can initially compensate for the augmented afterload (PVR) and maintain cardiac output, it is rarely fully compensatory and will eventually lead to RV failure. In line with this, our analysis of PRSW in untreated PAH rats demonstrated a lack of stroke work reserve in the RV.

The aforementioned results suggest a potential link between adrenoceptor activity, mitochondrial stress and cardiomyocyte hypertrophy. To investigate this correlation, we stimulated H9C2 cardiomyoblasts with phenylephrine, an adrenergic  $\alpha_1$ -agonist, and found that adrenergic stimuli associated with an increase in mitochondrial superoxide, which was alleviated by the addition of an antioxidant. We further investigated the relationship between adrenergic stimulated oxidative stress and cardiomyoblast hypertrophy and observed that phenylephrine-stimulated cardiomyoblasts were indeed hypertrophied. Notably, stimulated cardiomyoblasts treated with an antioxidant demonstrated reduced cellular hypertrophy, suggesting a strong link between the sympathetic pathway and myocardial oxidative stress, and its consequences to RV remodelling.

## Limitations

The monocrotaline model is one of the most commonly used animal models for PAH. Monocrotaline induces PAH through direct endothelial lesion formation, which is comparable to drug- and toxin-related PAH seen in humans. However, the monocrotaline model does not fully mimic complex idiopathic PAH, which is, clinically, the most common form of PAH [23]. Another limitation involves the time points used in assessing the effects of BS on PAH. Therefore, it was not possible to distinguish the direct effects of BS on the lungs from those on the RV, particularly because PVR is closely linked to afterload and thus RV failure. Since we studied BS prior to monocrotaline induction, we can only theorize its effects on patients with developed PAH. In this regard, sympathetic blockade was able to prevent PASM muscularization, the primary pathological change in PAH, as previously reported by other authors [9, 10]. Regarding the clinical practice, BS can be performed surgically by thoracoscopy, as routinely used in the treatment of patients with hyperhidrosis. About the best moment for the application on patients, given that myocardial remodelling is a continuous process, it seems reasonable to expect to have BS intervention performed immediately after the



PAH diagnosis or at any time point. Nonetheless, further investigations regarding BS are warranted to assess its potential benefits in pulmonary artery reverse remodelling.

## CONCLUSIONS

Bilateral thoracic sympathetic blockade prevented pulmonary vascular remodelling and RV failure in our experimental PAH model. While sympathetic activation evoked pulmonary arterial muscularization, elevated PVR, augmented myocardial oxidative stress and induced cardiac remodelling and failure, BS prevented all these pathophysiological changes and consequently maintained RV function. Our data suggest that BS may provide a therapeutic benefit to PAH patients.

## SUPPLEMENTARY MATERIAL

Supplementary material is available at *EJCTS* online.

## Funding

This work was supported by the Coordenação de Aperfeiçoamento de Pessoal de Nível Superior–Brasil (CAPES)–Finance Code 001.

**Conflict of interest:** none declared.

## Data Availability Statement

All relevant data are within the manuscript and its Supporting Information files.

## Author contributions

**Raphael dos Santos Coutinho e Silva:** Conceptualization; Data curation; Formal analysis; Investigation; Methodology; Project administration; Writing—original draft; Writing—review & editing. **Lucas Moritz Wiggerhauser:** Conceptualization; Data curation; Methodology; Writing—review & editing. **Rafael Simas:** Conceptualization; Data curation; Methodology; Writing—review & editing. **Fernando Luiz Zanoni:** Conceptualization; Data curation; Methodology; Writing—review & editing. **Geisla Medeiros:** Methodology; Writing—review & editing. **Fernanda Beatriz da Silva:** Methodology; Writing—review & editing. **Daniel Cury Ogata:** Methodology; Writing—review & editing. **Ana Cristina Breithaupt Faloppa:** Methodology; Writing—review & editing. **Guido Krenning:** Conceptualization; Data curation; Methodology; Writing—review & editing. **Luiz Felipe Pinho Moreira:** Conceptualization; Data curation; Funding acquisition; Methodology; Project administration; Resources; Supervision; Writing—original draft; Writing—review & editing.

## Reviewer information

European Journal of Cardio-Thoracic Surgery thanks Diego Gonzalez-Rivas, Nikolay O. Travin and the other, anonymous reviewer(s) for their contribution to the peer review process of this article.

## REFERENCES

- Prins KW, Thenappan T. World Health Organization Group I pulmonary hypertension: epidemiology and pathophysiology. *Cardiol Clin* 2016;34:363–74.
- Tuder RM, Archer SL, Dorfmueller P, Erzurum SC, Guignabert C, Michelakis E *et al.* Relevant issues in the pathology and pathobiology of pulmonary hypertension. *J Am Coll Cardiol* 2013;62:D4–12.
- Thenappan T, Ormiston ML, Ryan JJ, Archer SL. Pulmonary arterial hypertension: pathogenesis and clinical management. *BMJ* 2018 14;360:j5492.
- Zimmer A, Teixeira RB, Bonetto JHP, Bahr AC, Türck P, de Castro AL *et al.* Role of inflammation, oxidative stress, and autonomic nervous system activation during the development of right and left cardiac remodeling in experimental pulmonary arterial hypertension. *Mol Cell Biochem* 2020;464:93–109.
- Liu R, Zhang Q, Luo Q, Qiao H, Wang P, Yu J *et al.* Norepinephrine stimulation of alpha1D-adrenoceptor promotes proliferation of pulmonary artery smooth muscle cells via ERK-1/2 signaling. *Int J Biochem Cell Biol* 2017;88:100–12.
- Mercurio V, Pellegrino T, Bosso G, Campi G, Parrella P, Piscopo V *et al.* Cardiac sympathetic dysfunction in pulmonary arterial hypertension: lesson from left-sided heart failure. *Pulm Circ* 2019;9:1–10.
- Zanoni FL, Simas R, da Silva RG, Breithaupt-Faloppa AC, Coutinho E Silva RD, Jatene FB *et al.* Bilateral sympathectomy improves postinfarction left ventricular remodeling and function. *J Thorac Cardiovasc Surg* 2017;153:855–863. e1.
- Coutinho E Silva RDS, Zanoni FL, Simas R, Martins da Silva MHF, Armstrong Junior R, Correia CJ *et al.* Effect of bilateral sympathectomy in a rat model of dilated cardiomyopathy induced by doxorubicin. *J Thorac Cardiovasc Surg* 2020;160:e135–e144.
- Zhao Y, Xiang R, Peng X, Dong Q, Li D, Yu G *et al.* Transection of the cervical sympathetic trunk inhibits the progression of pulmonary arterial hypertension via ERK-1/2 signalling. *Respir Res* 2019;20:121.
- Na S, Kim OS, Ryoo S, Kweon TD, Choi YS, Shim HS *et al.* Cervical ganglion block attenuates the progression of pulmonary hypertension via nitric oxide and arginase pathways. *Hypertension* 2014;63:309–15.
- Zhou L, Zhang J, Jiang XM, Xie DJ, Wang JS, Li L *et al.* Pulmonary artery denervation attenuates pulmonary arterial remodeling in dogs with pulmonary arterial hypertension induced by dehydrogenized monocrotaline. *JACC Cardiovasc Interv* 2015;8:2013–23.
- Chen SL, Zhang FF, Xu J, Xie DJ, Zhou L, Nguyen T *et al.* Pulmonary artery denervation to treat pulmonary arterial hypertension: the single-center, prospective, first-in-man PADN-1 study (first-in-man pulmonary artery denervation for treatment of pulmonary artery hypertension). *J Am Coll Cardiol* 2013;62:1092–100.
- Chen SL, Zhang H, Xie DJ, Zhang J, Zhou L, Rothman AM *et al.* Hemodynamic, functional, and clinical responses to pulmonary artery denervation in patients with pulmonary arterial hypertension of different causes: phase II results from the Pulmonary Artery Denervation-1 study. *Circ Cardiovasc Interv* 2015;8:e002837.
- Good RB, Gilbane AJ, Trinder SL, Denton CP, Coghlan G, Abraham DJ *et al.* Endothelial to mesenchymal transition contributes to endothelial dysfunction in pulmonary arterial hypertension. *Am J Pathol* 2015;185:1850–8.
- Sheng Y, Zhu L. The crosstalk between autonomic nervous system and blood vessels. *Int J Physiol Pathophysiol Pharmacol* 2018;10:17–28.
- Damon DH. Sympathetic innervation promotes vascular smooth muscle differentiation. *Am J Physiol Heart Circ Physiol* 2005;288:H2785–2791.
- Channick RN, Simonneau G, Sitbon O, Robbins IM, Frost A, Tapson VF *et al.* Effects of the dual endothelin-receptor antagonist bosentan in patients with pulmonary hypertension: a randomised placebo-controlled study. *Lancet* 2001;358:1119–23.
- Klinger JR, Kadowitz PJ. The nitric oxide pathway in pulmonary vascular disease. *Am J Cardiol* 2017;120:S71–S79.
- Tuder RM, Flook BE, Voelkel NF. Increased gene expression for VEGF and the VEGF receptors KDR/Flk and Flt in lungs exposed to acute or to chronic hypoxia. Modulation of gene expression by nitric oxide. *J Clin Invest* 1995;95:1798–807.
- Cho YJ, Han JY, Lee SG, Jeon BT, Choi WS, Hwang YS *et al.* Temporal changes of angiotensin and Tie2 expression in rat lungs after monocrotaline-induced pulmonary hypertension. *Comp Med* 2009;59:350–6.
- Farkas L, Farkas D, Ask K, Möller A, Gaudie J, Margetts P *et al.* VEGF ameliorates pulmonary hypertension through inhibition of endothelial apoptosis in experimental lung fibrosis in rats. *J Clin Invest* 2009;119:1298–311.
- Gorski PA, Ceholski DK, Hajjar RJ. Altered myocardial calcium cycling and energetics in heart failure—a rational approach for disease treatment. *Cell Metab* 2015;21:183–94.
- Calderaro D, Alves Junior JL, Fernandes C, Souza R. Pulmonary hypertension in general cardiology practice. *Arq Bras Cardiol* 2019;113:419–28.